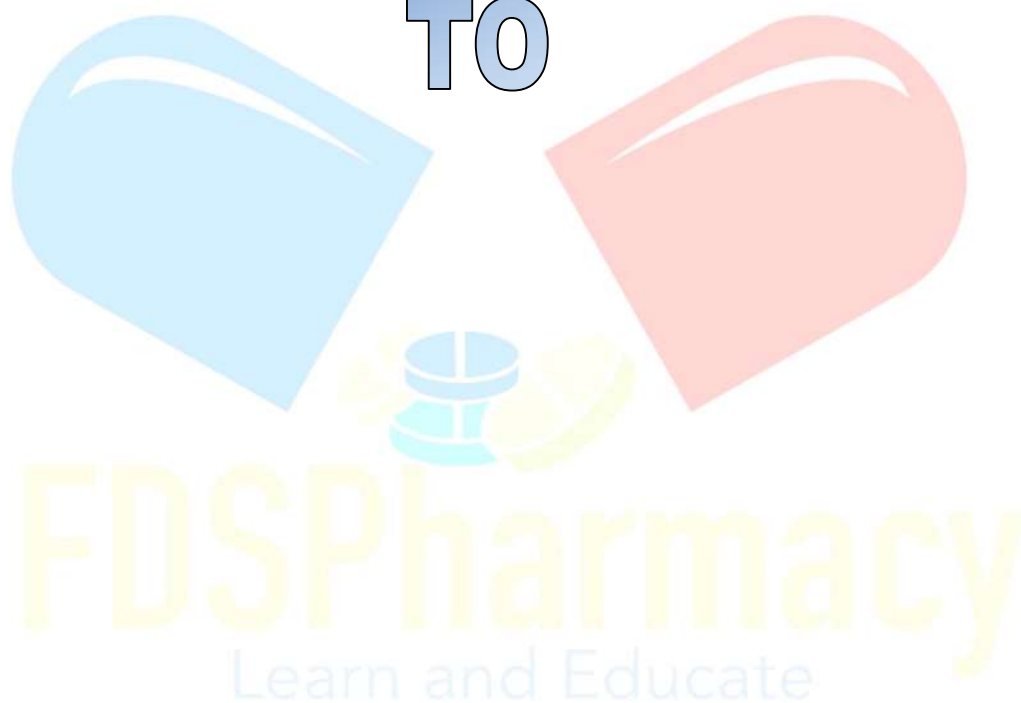

# WELCOME TO



This is an Education Platform

We Provide PDF Notes for Pharmacy Students

Web Site <http://www.fdspharmacy.in/>

You tube <https://www.youtube.com/c/FDSpharmacy>

Telegram <https://t.me/Fdspharmacy>

App <https://play.google.com/store/apps/details?id=com.FDSPharmacyMedia.FDSPharmacy>

E-mail [fdspharmacyinfo@gmail.com](mailto:fdspharmacyinfo@gmail.com)

## Bachelor of Pharmacy Communication skills

### NOTES

- ✓ Unit 1
  - ✓ Unit 2
  - ✓ Unit 3
  - ✓ Unit 4
  - ✓ Unit 5
- All Unit  
in  
One PDF**

Visit our Website  
[WWW.fdspharmacy.in](http://WWW.fdspharmacy.in)



## Bachelor of Pharmacy Human Anatomy and Physiology I

### NOTES

- ✓ Unit 1
  - ✓ Unit 2
  - ✓ Unit 3
  - ✓ Unit 4
  - ✓ Unit 5
- All Unit  
in  
One PDF**

Visit our Website  
[WWW.fdspharmacy.in](http://WWW.fdspharmacy.in)



## Bachelor of Pharmacy Pharmaceutical Analysis I

### NOTES

- ✓ Unit 1
  - ✓ Unit 2
  - ✓ Unit 3
  - ✓ Unit 4
  - ✓ Unit 5
- All Unit  
in  
One PDF**

Visit our Website  
[WWW.fdspharmacy.in](http://WWW.fdspharmacy.in)



## Bachelor of Pharmacy Pharmaceutical Inorganic Chemistry

### NOTES

- ✓ Unit 1
  - ✓ Unit 2
  - ✓ Unit 3
  - ✓ Unit 4
  - ✓ Unit 5
- All Unit  
in  
One PDF**

Visit our Website  
[WWW.fdspharmacy.in](http://WWW.fdspharmacy.in)



## Bachelor of Pharmacy Remedial Biology

### NOTES

- ✓ Unit 1
  - ✓ Unit 2
  - ✓ Unit 3
  - ✓ Unit 4
  - ✓ Unit 5
- All Unit  
in  
One PDF**

Visit our Website  
[WWW.fdspharmacy.in](http://WWW.fdspharmacy.in)



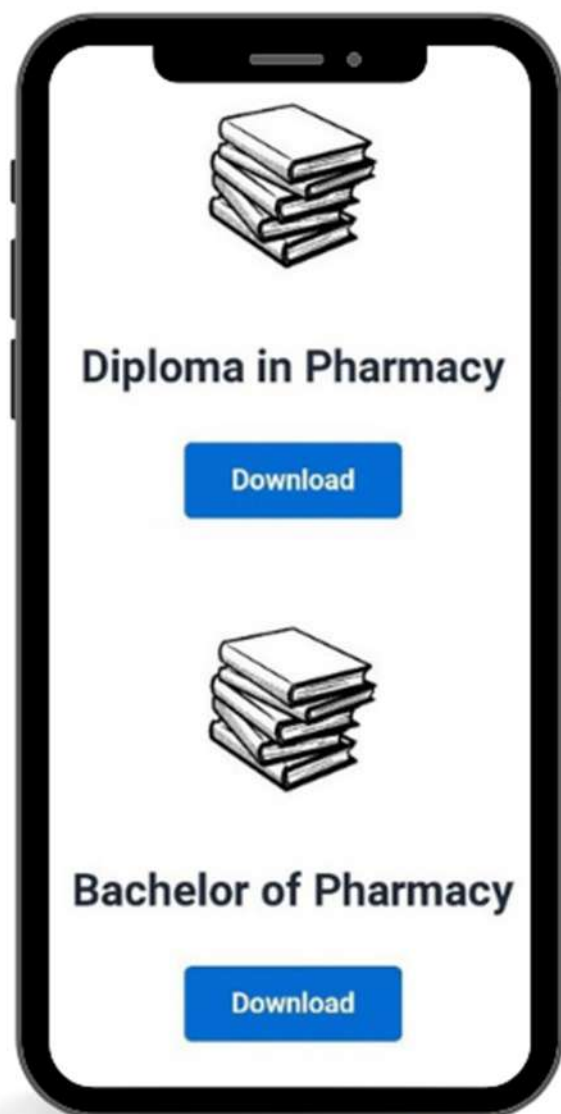## Bachelor of Pharmacy Pharmaceutics I

### NOTES

- ✓ Unit 1
  - ✓ Unit 2
  - ✓ Unit 3
  - ✓ Unit 4
  - ✓ Unit 5
- All Unit  
in  
One PDF**

Visit our Website  
[WWW.fdspharmacy.in](http://WWW.fdspharmacy.in)





## D.Pharma B.Pharma

- 👉 PDF Notes
- 👉 Practical Manual
- 👉 Important Questions
- 👉 Assignment etc

 **Download Now**



# [www.fdpharmacy.in](http://www.fdpharmacy.in)

# REMEDIAL BIOLOGY

## UNIT 2

TOPIC :

- **Digestion and Absorption**

Human alimentary canal and digestive glands

Role of digestive enzymes

Digestion, absorption and assimilation of digested food



# Digestive System

- Raw materials are utilised by the cells for production of energy which is further consumed for different synthetic processes.
- The external environment provides these raw materials in the form of food.
- The digestive system transfers nutrients from the external environment (in the form of food) to the internal environment (via ingestion of food).
- In the internal environment, nutrients are distributed to different cells of the body via circulatory system.
- Digestive system includes the alimentary canal (gastrointestinal tract), some accessory digestive glands, and a range of digestive processes which take place at different levels in the alimentary canal for the absorption of digested food.
- The process of breakdown and absorption of the consumed food is termed as digestion.
- It involves the following processes:
  - Mechanical breakdown of food by processes like chewing, mixing, churning, and segmentation.
  - Chemical breakdown of food into their chemical building blocks via digestive enzymes present in the secretion of digestive glands and the accessory organs of the digestive system.

## Anatomy of Digestive Intestinal Tract (GIT)

- The alimentary canal ( or the gastrointestinal or digestive tract) begins at the mouth and terminates at the anus.
- All the different parts are named separately, though they are more or less similar in structure.

- After ingestion the food passes through this long tube to reach the stomach and intestines for further digestion, absorption, and assimilation.
- Different parts of the alimentary canal include:
  - Oral cavity (mouth),
  - Pharynx,
  - Oesophagus,
  - Stomach,
  - Small intestine,
  - Large intestine, and
  - Accessory organs of the digestive system:
    - i) Three pairs of salivary glands,
    - ii) Pancreas,
    - iii) Liver, and
    - iv) Gall bladder

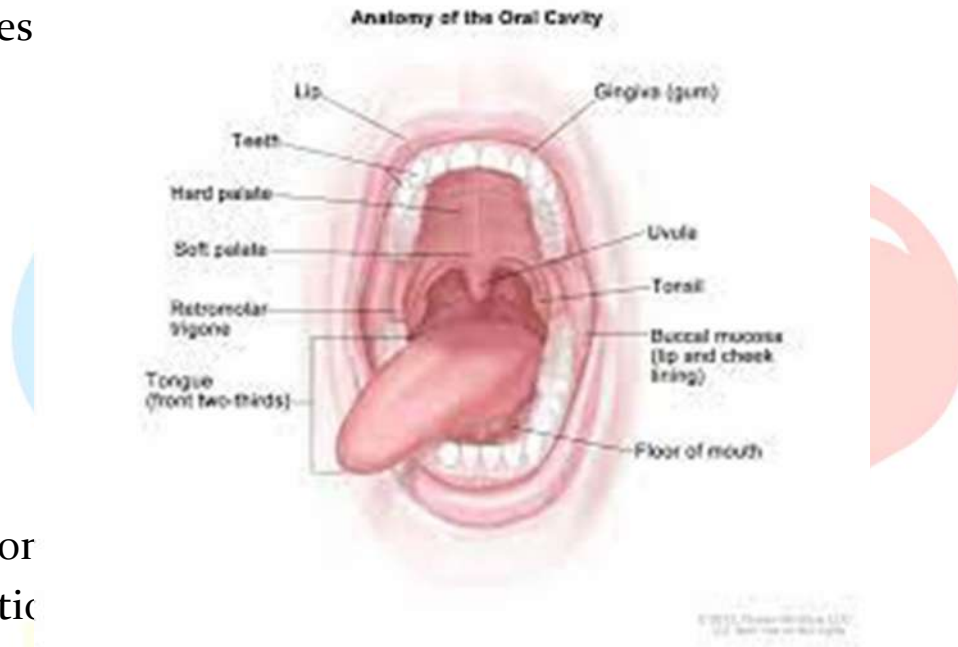
### Oral Cavity (Mouth)

- Oral cavity forms the first part of the alimentary canal.
- It is surrounded by various muscles and bones which are as follows:
  - **Anteriorly** : The anterior wall is bound by the lips.
  - **Posteriorly** : The posterior wall continues with the oropharynx.
  - **Laterally** : The lateral walls are bound by the cheek muscles.
  - **Superiorly** : The superior wall is bound by the bony hard palate and muscular soft palate.
  - **Inferiorly** : The inferior wall is bound by the muscular tongue and the soft tissues of the floor of mouth

### Anatomy

- The roof of oral cavity is formed by the palate.
- The anterior part is referred to as the hard palate.
- while the posterior part forms the soft palate.

- The maxilla and palatine bones form the hard palate.
- The posterior end of the hard palate is continuous with the muscular soft palate.
- which curves downwards merging with the pharyngeal walls on both the sides



## Functions

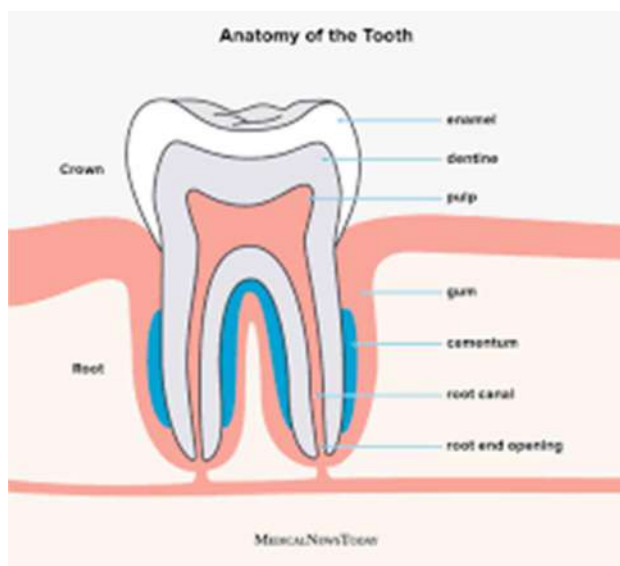- ✓ Ingestor
- ✓ Perceptive
- ✓ Lubrication of food,
- ✓ Mechanical digestion of food with the help of salivary enzymes,
- ✓ Aids in speech, and
- ✓ Acts as a source for delivery of drugs.

## Teeth

- As soon as the food is taken in the mouth, it is chewed with the help of teeth to breakdown into smaller particles.
- This process is known as mastication.
- Teeth are hard calcified structures that help in mastication, and thus aid in the process of mechanical digestion.
- Teeth can functionally be divided into two broad categories, viz., the deciduous teeth (baby or milk teeth; 20 in number) and the permanent teeth (adult teeth; 32 in number).
- Deciduous teeth are replaced with permanent teeth in around 6-7 years of age

## Anatomy

- The basic structure of a tooth includes a crown (the visible part) and a root (the part within the gum, holding the tooth firmly).
- The crown is covered with enamel (a highly mineralised tissue) and the root is covered with cementum (hard connective tissue).
- The part connecting the crown and the root portion of a tooth is referred to as the neck.
- Crown consists of enamel and dentin.
- Enamel is the hardest and the most mineralised entity of the human body; it forms the outermost covering in a tooth.
- The major mineral present in it is calcium phosphate (in the form of hydroxyapatite ).
- Dentin (a hard connective tissue just like bone) is the layer present beneath the enamel and accounts for the largest portion of the tooth.
- It surrounds the pulp (a soft connective tissue comprising of blood vessels and nerves innervating the tooth).
- The pulp tissue, dentin, and cementum cover the root from inside out.
- The root is held to the dental alveolus (bony socket) via periodontal ligament (specialised connective tissue fibres).
- The nerves and blood vessels present in the pulpal tissue enter and exit via apical foramen ( opening at the apex of a tooth root).



## Types and Functions

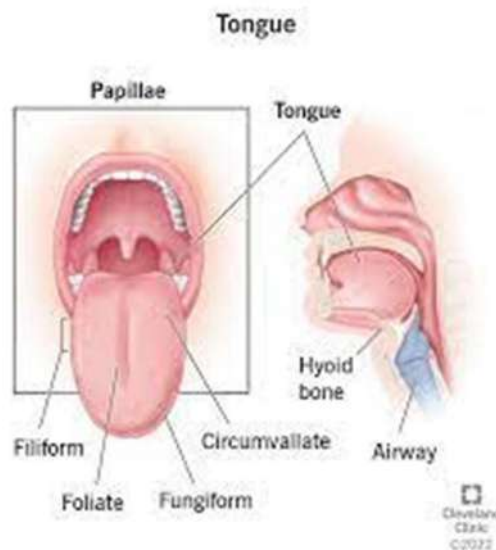
- ✓ **Incisors** : These teeth aid in biting-off large pieces of food.
- ✓ **Cuspids/Canines** : These conical-shaped teeth aid in grasping and tearing the food.
- ✓ **Bicuspid/Premolars** : These teeth help in grinding the food; they are absent in children (appear only after 9 years of age).
- ✓ **Molars** : These are the largest teeth and are present at the back of the mouth. They also aid in grinding the food.

## Tongue

- Tongue is a muscular organ situated on the floor of the mouth , which helps in chewing and swallowing of food (deglutition).
- A large amount of nerve and blood vessels innervates the tongue there by helping in its movement.

## Anatomy

- Tongue (derived from the Latin term lingua and Greek term glossa ), is located at the floor of the mouth.
- It is attached to the hyoid bone, mandible, styloid processes, and pharynx via muscles.
- It consists of a tip (tongue tip), margin, dorsum, ventral (inferior) surface, and root. The root of the tongue rests against the incisors.



## Functions

- ✓ Tongue houses various taste buds thus helps in Perception of the taste of food. The taste buds also help in sensing whether the food is noxious (harmful) or not.
- ✓ It plays a significant role in the digestive process. It helps in the movement of food within the oral cavity to be available for chewing and grinding.
- ✓ It also helps in the formation of bolus which is then swallowed.
- ✓ It also helps in speech and phonetics where it helps producing different sounds by altering the shape of the wind pipe and by repositioning the tongue. Thus, the vocal cords are able to produce sound.

## Pharynx

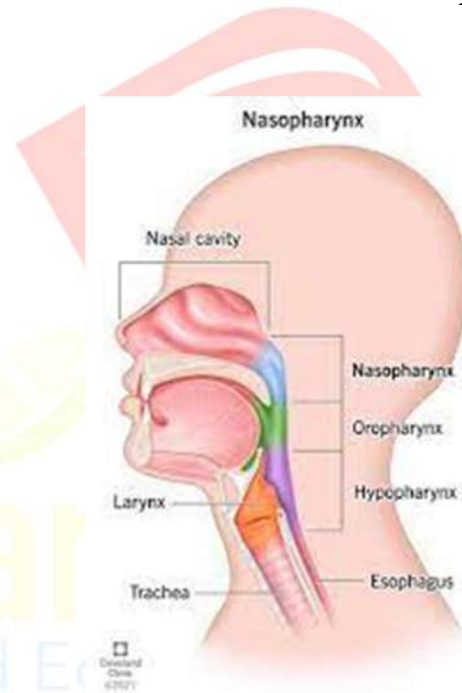
→ Pharynx (throat) is a funnel-shaped tube extending from the internal nares to the posterior part of oesophagus and anterior part of larynx. Pharynx is made up of skeletal muscles, lined with mucous membrane and is divided into nasopharynx, oropharynx, and laryngopharynx.

## Anatomy

- In humans, the pharynx can be divided into three parts
- Nasopharynx: This part of the Pharynx lies immediately posterior to the nasal cavity. The postero-superior boundary of nasopharynx extends from the junction of the hard and soft palates till the base of the skull; the inferior boundary is formed by the superior surface of the soft palate and the lateral walls are formed by the fossa of Rosenmüller.
- Oropharynx: This part of the pharynx lies immediately posterior to the oral cavity. The anterior wall of the oropharynx is formed by the base of the tongue and the vallecula (its depression) the superior boundary is marked by the junction between the hard and soft palates the inferior boundary begins posterior to the circumvallate papillae of the

tongue and the lateral wall is made up of tonsil, tonsillar fossa, and tonsillar (faucial) pillars.

- Hypopharynx or Laryngopharynx: This part of the pharynx lies just inferior to the oropharynx and superior to the oesophagus. The name laryngopharynx corresponds to the levels of cervical vertebrae C<sub>3</sub> to C<sub>6</sub>. It is bounded by the posterior pharyngeal wall and also includes the piriform sinus and the postcricoid mucosa. It is anteriorly bounded by the epiglottis and the larynx.



## Functions

The functional activities of pharynx are :

- ✓ Passageway for Air and food
- ✓ Taste
- ✓ Warming and Humidifying
- ✓ Hearing
- ✓ protection

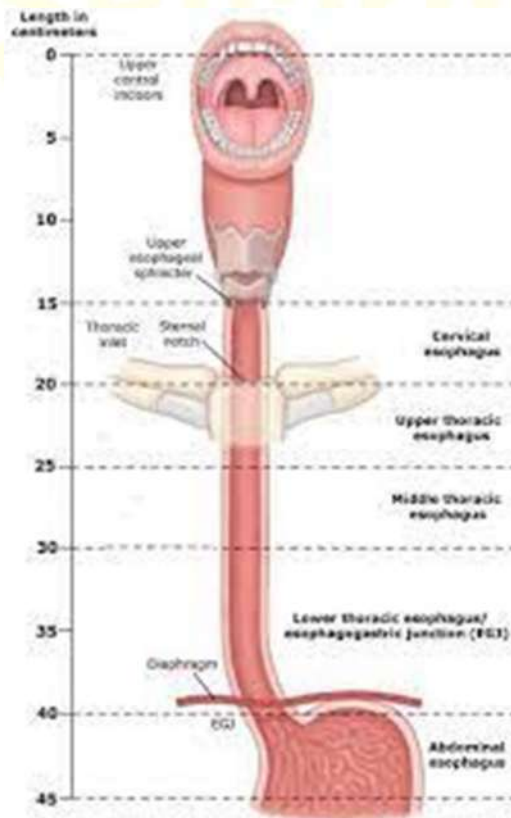
## Oesophagus

→ Oesophagus or the food pipe is a long muscular tube (10 inches or 25cm long) which forms a passage for the food to pass from the pharynx to the stomach. It begins at the inferior end of the laryngopharynx, lies posterior to the trachea, and is anteriorly bounded by the trachea.

- The oesophagus continues from the hypopharynx at the level of C6 vertebra.
- When the food is swallowed, the oesophagus walls squeeze together (contract) to move the food down the oesophagus to the stomach.
- The upper part of oesophagus lies posteriorly but separate from the trachea or windpipe.
- The oesophagus joins the stomach at the gastro-oesophageal junction}

## Anatomy

- **Mucosa** : Oesophagus is covered by mucosa.
- **Submucosa** : This layer lies beneath the mucosa and comprises of mucous- secreting glands ( oesophageal glands ) The connective structures present in this layer are known as papillae.
- **Muscularis Externa (or Muscularis Propria)** : This is the innermost layer lying beneath the submucosal layer.



## Functions

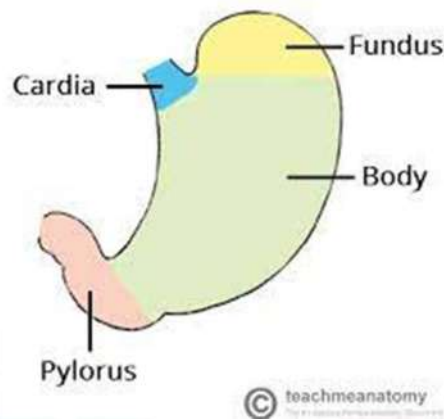
- ✓ Oesophagus mainly performs the function of deglutition (swallowing).
- ✓ This process is completed in three stages once the masticatory process is over and bolus has been formed.
- ✓ Though the initiation of deglutition is voluntary; however, its completion is by an involuntary (reflex) action

## Stomach

- Stomach is a hollow, muscular, bag-like structure.
- It differs in size and shape in every individual from time to time, depending upon the contents present in the stomach.
- Body posture is another factor that alters its shape and size at any given moment of time.
- Stomach lies between the oesophagus and the small intestine.
- The second phase of digestion (after mastication) takes place in the stomach where the food (or bolus) is broken down into smaller components before being passed on to the remaining parts of the digestive system.

## Anatomy

- Stomach is positioned on the left side of the abdominal cavity, between the oesophagus and the duodenum (uppermost part of the small intestine). Anatomically, stomach can be divided into four regions)
- Each region varies from the other in terms of cellular organisation and functions. They are:
  - ◆ **Cardia** : This part is continuous from the oesophagus.
  - ◆ **Fundus** : This dome-shaped part is formed by the upper curvature of the stomach.
  - ◆ **Body or Corpus** : This is the central region of the stomach.
  - ◆ **Pylorus or Antrum** : This is the lower region of the stomach that continues into the duodenum.



## Functions

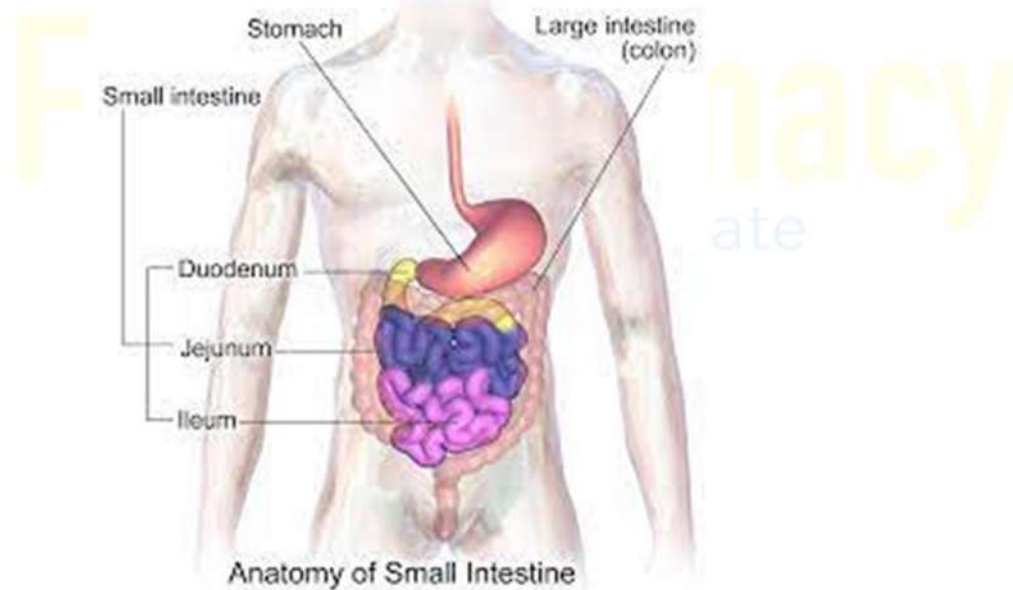
- Stomach performs the following functions :
- It provides highly acidic environment due to gastric acid production and secretion which produces a luminal pH range 1 to 3 depending on the species, food intake, time of the day, drug use, and other factors. Such an environment is able to breakdown large molecules (such as from food) into smaller ones so that they can eventually be absorbed from the small intestine.
- It secretes about 2-3 litres of gastric acid per day with basal secretion levels being typically highest in the evening.
- Pepsinogen is secreted by the chief cells of stomach wall and turns into pepsin under low pH conditions and is helpful in protein digestion.
- Absorption of vitamin B<sub>12</sub> from the small intestine is dependent on conjugation to a glycoprotein called intrinsic factor which is produced by the parietal cells of stomach.

## Small Intestine

- Small intestine is a portion between the stomach and the large intestine.
- It is a long, highly convoluted tube in the digestive system that absorbs about 90% of the nutrients from the ingested food.

- It is the main site of absorption.
- Its internal wall is folded to form villi (finger-like tissues).
- Each of these villi is further covered with microvilli (even smaller finger-like projections).
- The presence of both villi and microvilli increase the surface area available for nutrients absorption
- Small intestine extends throughout the abdominal cavity inferior to the stomach.
- In adult humans, it measures about 7m in length (though it may vary from 4-7m) and 2.5-3cm in diameter.
- It is around 4-5 times longer than the large intestine, however, it is known that the diameter of small intestine is relatively smaller than that of the large intestine

## Anatomy



## Functions

Small intestine performs the following functions:

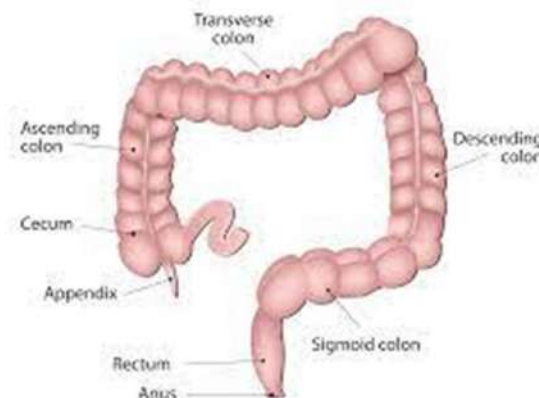
- ✓ It forms a passage way for the movement of food into the large intestine by peristaltic movements.
- ✓ It receives the secretions of pancreas and liver to aid in digestion.

- ✓ The process of chemical digestion of carbohydrates, proteins, and fats is completed in the small intestine,
- ✓ It secretes two significant hormones, cholecystokinin (CCK) and secretin.
- ✓ It is the site for absorption of nutrients.
- ✓ The solitary lymph follicles and aggregated lymph follicles provide protection from microbes that survived the antimicrobial action of the hydrochloric acid produced in the stomach.

### Large Intestine

- Large intestine forms the last part of the alimentary canal.
- It extends from the caecum to the anus, while including the ascending colon, transverse colon, descending colon, sigmoid colon, and the rectum.
- It absorbs water and vitamins while converting the digested food into faeces.
- At the same time, it stores the waste matter before it is eliminated from the body.
- Large intestine wraps around the border of the abdominal body cavity from the right side of the body, across the top of the abdomen, and finally down the left side, In adult humans, it is about 1.5m in length, i.e., nearly one-fifth of the entire length of the intestine, and 6-7cm in diameter.
- Although shorter in length than the small intestine, large intestine is considerably thicker in diameter.

### Anatomy



## Functions

Large intestine performs the following functions:

- ✓ Secretions from the large intestine lubricate the faeces, facilitating their passage via rectum and the anus.
- ✓ It houses bacteria (e.g., *E. coli*, *S. faecalis*, and *C. welchii*) which act on different undigested and unabsorbed food material. These bacteria synthesise vitamin K and folic acid.
- ✓ It forms the site for absorption of water, glucose, and salt.
- ✓ Intestinal walls form the site for excretion of excess amounts of calcium, iron, and drugs of the heavy metals.
- ✓ Segmental contractions occur in the large intestine which helps in mixing of the matter inside the colon. On the other hand, the peristaltic contractions of large intestine push the matter towards the rectum, which is ultimately evacuated.
- ✓ The descending and sigmoid colon undergo mass action contractions, in which a large portion of the intestine contracts simultaneously, promoting defecation.

## Salivary Glands

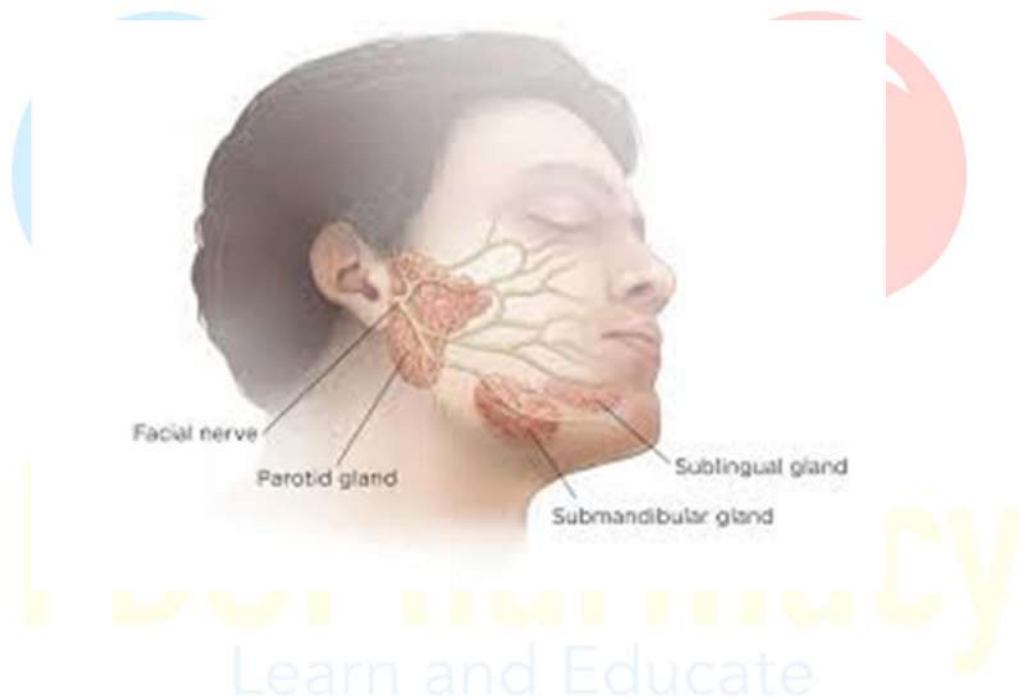→ Three pairs of large multicellular salivary glands are present in the mouth:

1. **Parotid Glands** : These are paired and largest salivary gland. They are located immediately anterior to the ear on either sides and produces serous secretions. Secretion of these glands is released by the parotid duct which opens adjacent to the upper second molar in the oral cavity.
2. **Submandibular Glands** : These are second largest gland and are also paired. They are located below the mandible (thus the name submandibular). Secretion of these glands is mixed types. i.e., both serous and mucous secretions. Secretion of this gland is released via a

submandibular duct which opens in the mandibular region of the oral cavity. adjacent to the frenulum of the tongue.

3. **Sublingual Glands :** These are the smallest and are also paired glands. These glands secrete mucous. These are ductless glands. Instead, each sublingual gland opens into the floor of the oral cavity through 10-12 small ducts.)

## Anatomy



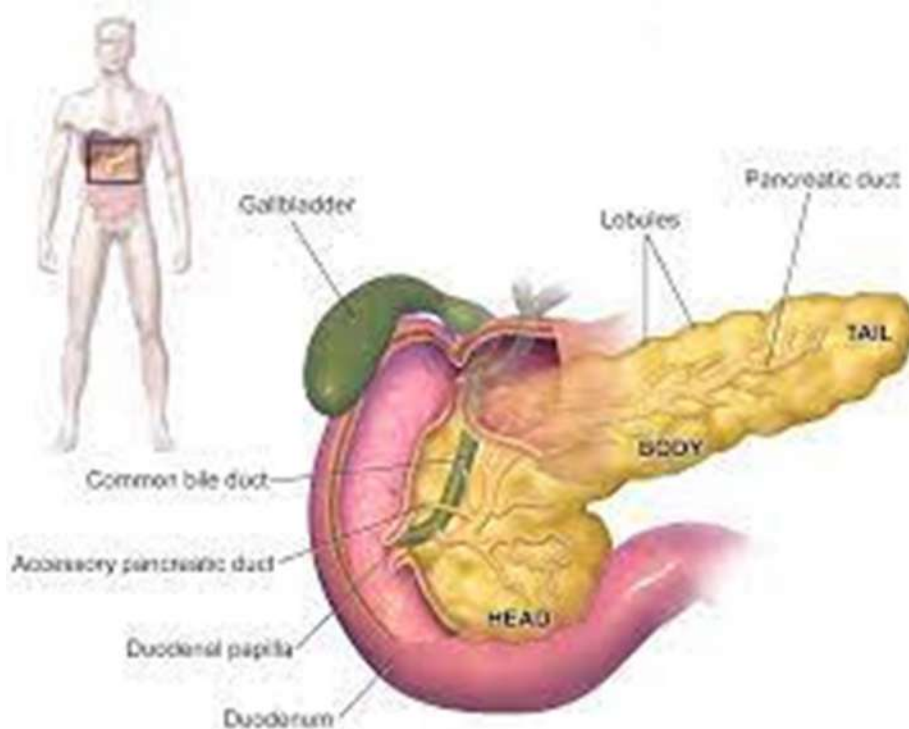
## Functions of Saliva

- ✓ The rate of secretion of saliva is approximately 1- 1.5L/day.
- ✓ Salivary amylase, a component of serous salivary secretion, helps in the breakdown of carbohydrates.
- ✓ Mucin (a proteoglycan) is a component of mucous secretions of the submandibular and sublingual glands.
- ✓ Mucin is secreted in large amounts by these glands and is responsible for the lubricating property. Saliva has antibacterial properties due to the presence of substances like lysozyme and immunoglobulin A.

## Pancreas

- Pancreas is an elongated, digestive gland: its size measures 6-10 inches and its weight is 65gm.
- It is spongy and shaped like a flat pear or a fish extended horizontally across the abdomen.
- It is located behind the stomach in the upper left abdomen, and close to the duodenum.
- It is the largest gland of the digestive system.
- It is formed by many lobules, and both exocrine and endocrine tissues.
- Pancreas plays an essential role in converting the ingested food into fuel for the body's cells.
- It is a mixed gland producing both exocrine (pancreatic juice containing digestive enzymes) and endocrine (insulin, glucagon, and somatostatin) secretions.

### Anatomy



## Functions

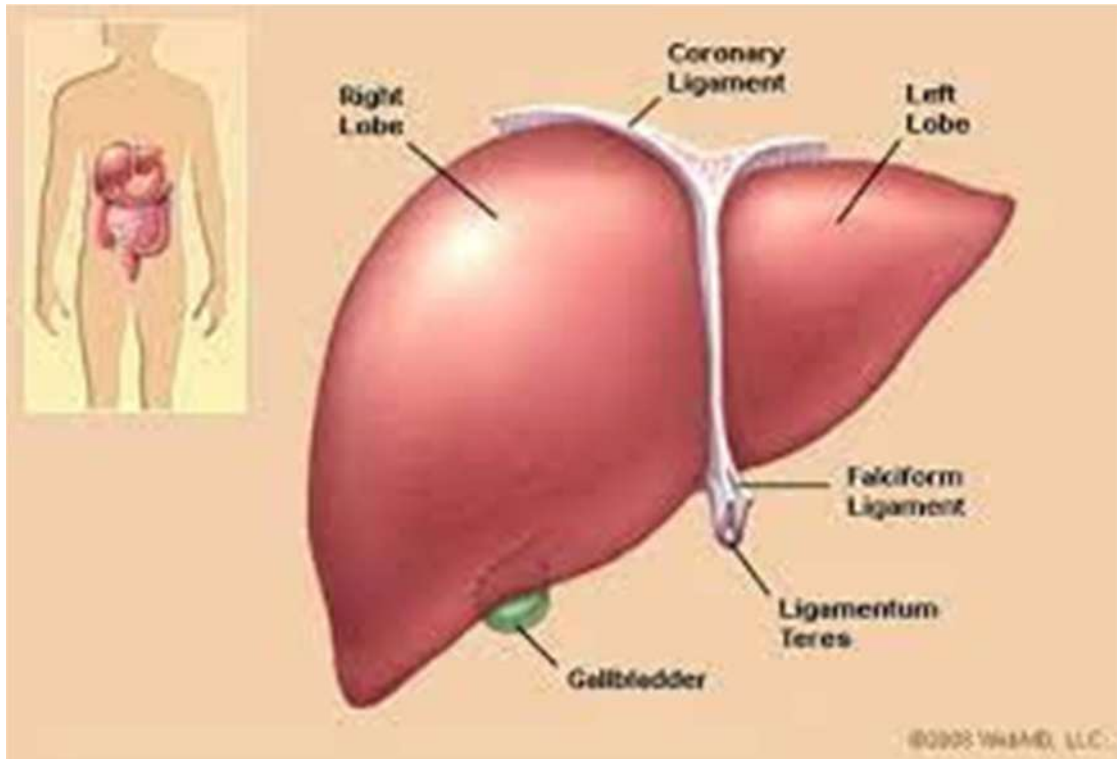
Functions of the pancreas are digestive and hormonal and can be explained as follows:

- ✓ **Exocrine Function** : The inactive enzymes of the pancreatic exocrine gland move down the pancreatic duct to reach the bile duct. These enzymes are activated only when they enter the duodenum. The carbohydrates, fats, proteins, and acids in the duodenum are broken down by these enzymes. A bicarbonate is also secreted by the exocrine tissue to neutralise the stomach acids in the duodenum.
- ✓ **Hormonal Function** : Insulin and glucagon are the main hormones secreted by the pancreatic endocrine gland. These hormones regulate the level of glucose and somatostatin in the blood.

## Liver

- Liver is the largest gland of the human body.
- It forms the second largest organ (skin is the largest organ).
- It lies just inferior to the diaphragm in the right side of the abdomino thoracic region.
- It weighs about 1.4kg, is reddish-brown in colour, and feels rubbery when touched.
- Along with digestion, liver performs various other functions like (detoxification, protein synthesis, and production of chemicals (bile) used in digestion.
- It also filters the blood coming from the digestive tract, before passing it to the rest of the body.
- It detoxifies chemicals and metabolises the drugs.
- Meanwhile it also secretes bile that ends up back in the intestines.
- The liver also makes proteins essential for blood clotting and other functions.

## Anatomy



## Function

- ✓ Carbohydrates Metabolism
- ✓ Lipid Metabolism
- ✓ Protein Metabolism
- ✓ Processing of Drugs and hormones
- ✓ Extraction of bilirubin
- ✓ Synthesis of Bile salts
- ✓ Storage

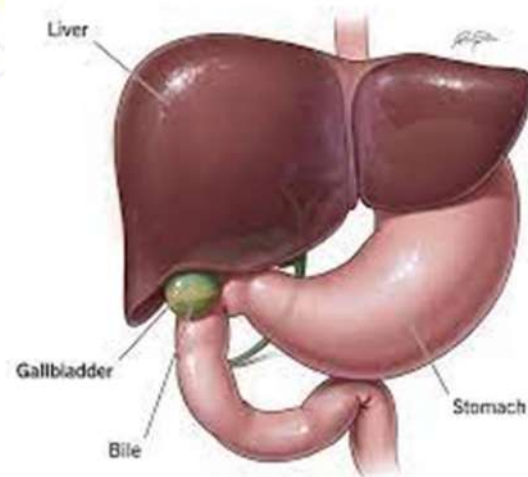
## Gall Bladder

- Gall bladder is a pear-shaped organ present on the inferior surface of the liver on the right side of the abdomen.
- This membranous muscular sac like structure is nearly 8cm in length and 4cm in width

- After meals, the gall bladder becomes empty and flat (like a deflated balloon): while before meals, it is filled with bile and is about the size of a small pear.
- Gall bladder functions to store and concentrate bile, which is produced by the liver and helps in digestion process.
- It has a capacity of about 70ml.

## Anatomy

- Gall bladder comprises of a fundus (broad part), the body, (central part), and the neck (impered part).
- The body and neck extend superiorly.
- The fundus extends inferiorly away from the inferior border of the liver
- Wall of the gall bladder is lined by three layers of tissues:
  - An Inner mucosal layer which is folded into rugae. thus enabling expansion of the gall bladder,
  - A muscularis layer which is a layer of smooth muscles enabling contraction of the gall bladder, and
  - An outer layer of serosa.



## Functions

- ✓ Storehouse for Bile
- ✓ Anti-Oxidant
- ✓ Acid Neutralisation
- ✓ Emulsification of Lipids
- ✓ Facilitation of Absorption
- ✓ Elimination of Waste Products

# Digestive Enzymes

- Digestive enzymes produced by the salivary glands, tongue, stomach, pancreas, and small intestine. These enzymes are responsible for catalysing various reactions in alimentary canal
- The various enzymes secreted by various parts of GI tract and their roles are as follows:
  - ▲ Salivary amylase: It is secreted by salivary glands. This enzyme is responsible for breakdown of starch.
  - ▲ Lingual lipase: It is secreted by lingual glands in tongue. This enzyme is responsible for breakdown of triglycerides.
  - ▲ Pepsin: It is secreted by stomach. This enzyme is responsible for breakdown of proteins.
  - ▲ Gastric lipase: It is secreted by stomach. This enzyme is responsible for breakdown of triglycerides.
  - ▲ Pancreatic amylase: It is secreted by pancreas. This enzyme is responsible for breakdown of starch.
  - ▲ Trypsin, chymotrypsin, carboxypeptidase, and elastase: These enzymes are secreted by pancreas. These enzymes are responsible for breakdown of proteins.
  - ▲ Pancreatic lipase: It is secreted by pancreas. This enzyme is responsible for breakdown of triglycerides.
  - ▲ Ribonuclease and deoxyribonuclease: These enzymes are secreted by pancreas. These enzymes are responsible for breakdown of nucleic acids.
  - ▲ Dextrinase, maltase, sucrase, and lactase: These enzymes are secreted by small intestine. These enzymes are responsible for breakdown of carbohydrates.

- ▲ **Aminopeptidase and dipeptidase:** These enzymes are secreted by small intestine. These enzymes are responsible for breakdown of proteins.

### **Digestion & Absorption**

→ The whole process of digestion can be divided into the following steps:

- **Ingestion :** In this step, food enters into the alimentary canal through the mouth, and is chewed and mixed with saliva containing enzymes ptyalin or amylase. Breakdown of carbohydrate and lipid starts by the ptyalin and lingual lipase enzymes, respectively. The process of chewing increases the surface area of the food, and the food mixed with saliva is called bolus.
- **Propulsion :** Tongue and pharyngeal muscles propel the bolus into the oesophagus. This phenomenon of swallowing is the last voluntary act up to defecation and is an example of propulsion, which involves movement of food through the alimentary canal. Propulsion includes the voluntary process of swallowing as well as the involuntary process of peristalsis. Peristalsis or peristaltic wave is defined as the sequential, alternating waves, of contraction and relaxation of alimentary wall smooth muscles, which propels the food to move forward Peristaltic waves also help in mixing the food with digestive juices.
- **Mechanical and Chemical Digestion :** Digestion involves both mechanical and chemical digestion. Mechanical (physical) digestion is a physical process that does not affect the chemical nature of the food; instead, it breaks food in smaller particles to increase both surface area and mobility.
- Chemical digestion of food starts in the mouth. In this process, the complex food particles are broken down into their chemical building blocks by the various digestive secretions (e.g., lipid separate into fatty acids).

**Absorption :** The food that has been disintegrated into simpler units is of no value unless it enters the blood circulation and its nutrients are utilised. It occurs by the absorption process which takes place mainly in the small intestine. Absorption of food occurs by the following five mechanisms:

- Active Transport
  - Passive Diffusion
  - Facilitated Diffusion
  - Co-transport
  - Endocytosis
- **Defecation :** It is the final step in which the undigested materials are voluntarily removed from the body as faeces

### **Assimilation of Food**

- Assimilation of food starts only after digestion of food. One has to remember that food digested is not food assimilated. Carbohydrates and proteins are digested first, in the stomach by the action of strong acid and enzymes, while the fats digested to fatty acids in intestine.
- Assimilation takes place only in small intestine, Intestine is provided with tiny projections known as microvilli on the preface of the cells lining the intestine which are known as epithelial cells. These epithelial cells take nutrients from intestine and pump into the blood, where from it is distributed to body for growth and repair.